

# Presurgical Infant Orthopedics: Nasoalveolar Molding

Inês Francisco<sup>1</sup>, Luísa Maló<sup>1</sup>, Ana Roseiro<sup>1</sup>, Sandra Ferreira<sup>2</sup>, Francisco Fernandes do Vale<sup>1</sup>

<sup>1</sup>Postgraduate in Orthodontics, Faculty of Medicine of University of Coimbra

<sup>2</sup>Department of Maxillofacial Surgery- Coimbra University Hospital Centre



26<sup>o</sup> CONGRESSO  
ORDEN DOS MÉDICOS DENTISTAS  
PORTUGUESE DENTAL ASSOCIATION ANNUAL MEETING

## Case Description

Cleft lip and palate is one of the common facial deformities<sup>1</sup>. Alveolar and nasal reconstruction is a challenge for the reconstructive surgeon. Presurgical nasoalveolar molding was introduced to mold the maxillary, alveolar, and nasal tissues prior to first surgical repair. Nasoalveolar molding also stimulated immature nasal chondroblasts, producing an interstitial expansion, which can improve nasal morphology. This appliance allowed the alignment of the intraoral alveolar segments and correction of the nasal tip, columella, the alar base and the philtrum<sup>2-4</sup>. This paper aims to describe the treatment of two newly born male infants where presurgical orthopedic therapy was used.

Two newly born male babies with a left cleft lip and palate. At two days of birth the impression for nasoalveolar molding was made. On the 15th day, we started alveolar modeling for six weeks. Nasal modeling was made for the next six weeks. The baby was seen weekly to make adjustments to the molding plate. The nasoalveolar molding appliance was secured extraorally to the cheeks bilaterally by surgical tapes with orthodontic elastic bands at one end.

### Treatment Protocol

#### 0-2 weeks

- Flattening and widening of the nostril aperture
- Prolabium everted
- Columella is slightly
- Overprojection of the premaxilla

#### Phase I

- Align the intraoral alveolar segments

#### Phase 2

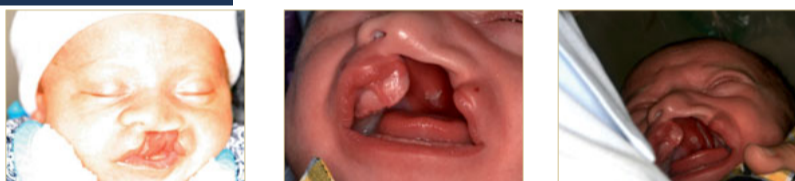- Incorporation of nasal stent (when the width of alveolar gap is reduced to about 5 mm)

#### Treatment objectives

- Elongation of the columella
- Decrease in the nasal alar base width
- Centering of the premaxilla along the midsagittal plane
- Retraction of the premaxilla along in a slow and gentle process to achieve continuity with the posterior alveolar cleft segments

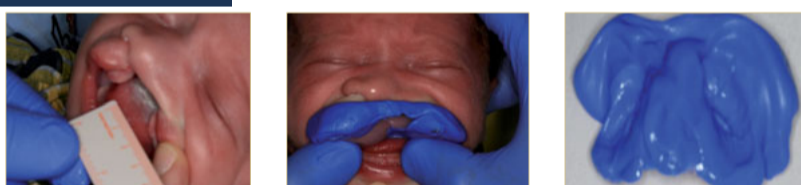### Case 1

#### 1 week of life



Figures 1-3: Initial photographs

#### 2 week of life




Figures 4-6: Impression technique. Cleft lip and palate with 3,5 cm.

#### Insertion and adjustment of Nasoalveolar Molding



Figures 7-10: Insertion of nasoalveolar molding and case evolution

#### Cleft Closure



Figures 11-12: After surgical lip and palate closure


### Case 2

#### 1 week of life



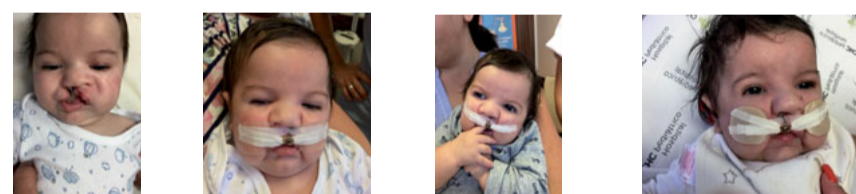
Figures 13-14: Initial photographs

#### 2 week of life



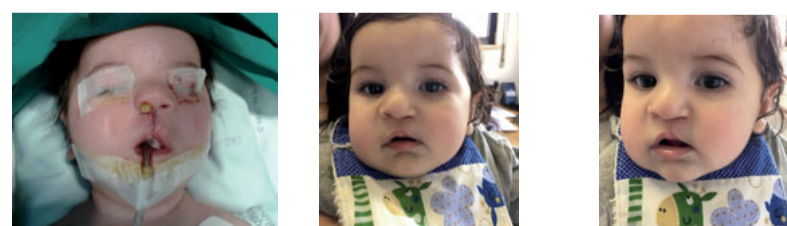
Figures 15-16: Impression technique

#### Insertion and adjustment of Nasoalveolar Molding



Figures 17-18: Insertion of nasoalveolar molding and case evolution

#### Cleft Closure



Figures 19-21: After surgical lip and palate closure

## Discussion

The tissue molding we achieved was measured on the lip approximation and was reduced from 3cm to 0,9cm on one subject and 3cm to 1,2cm on the other one.

## Conclusion

Presurgical orthopedic therapy of the cleft infant is intended to reduce severity of the oronasal deformity prior to surgery. Molding the nasal cartilage, premaxilla and alveolar ridges in the neonatal period with surgical procedures results in better aesthetics and a reliable longterm result.

## Bibliography