



# Increase of Keratinized Gingiva in the 5<sup>th</sup> Sextant: Clinical Cases



Catarina Martinho, Ana Ribeiro Soares, Cátia Ferreira da Silva, João Miguel Gomes, Susana Noronha

POST-GRADUATION COURSE IN PERIODONTOLOGY – FACULTY OF DENTAL MEDICINE (UNIVERSITY OF LISBON)

## Clinical Cases Description

**Case 1**  
Female patient, 42 years-old, healthy, with complaints of discomfort associated with the buccal gingiva of tooth 41.

After clinical observation, a Miller class III gingival recession<sup>1</sup>, with a narrow band of keratinized gingiva and a high insertion of the labial frenum was observed, preventing an adequate bacterial plaque control by the patient.

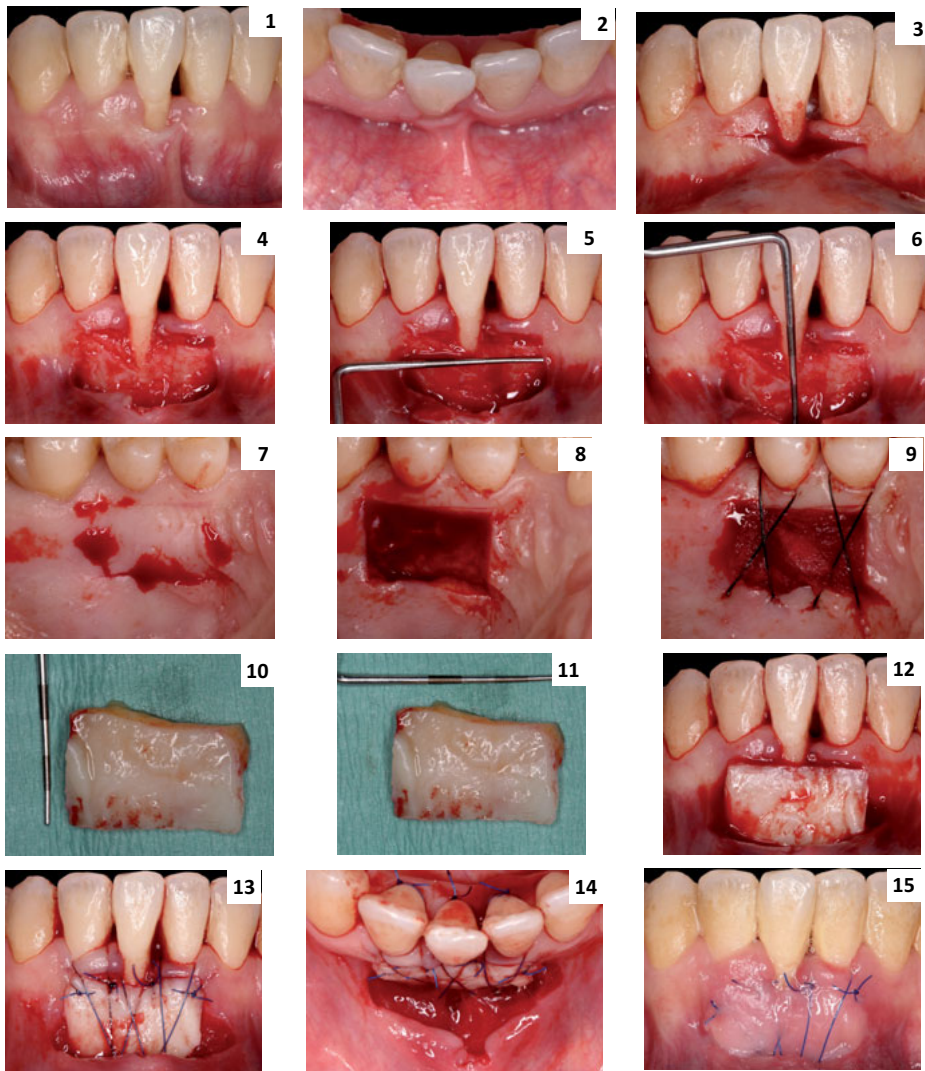
### Case 1

**Case 2**  
Female patient, 62 years-old, without relevant medical conditions, with complaints of discomfort associated with the buccal gingiva of tooth 41.

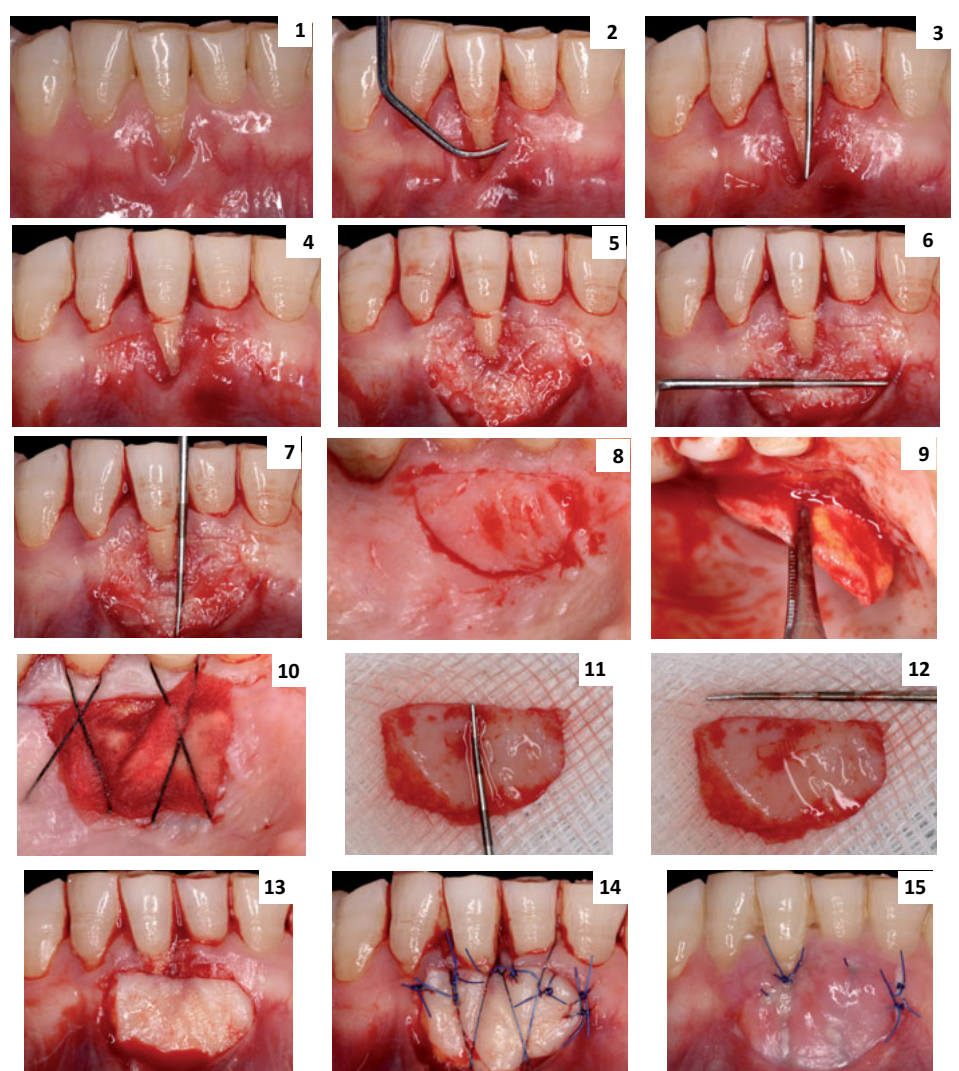
After clinical observation, a Miller class II gingival recession<sup>1</sup>, with a narrow band of keratinized gingiva and persistent inflammation was observed, preventing an adequate bacterial plaque control by the patient.

### Case 2

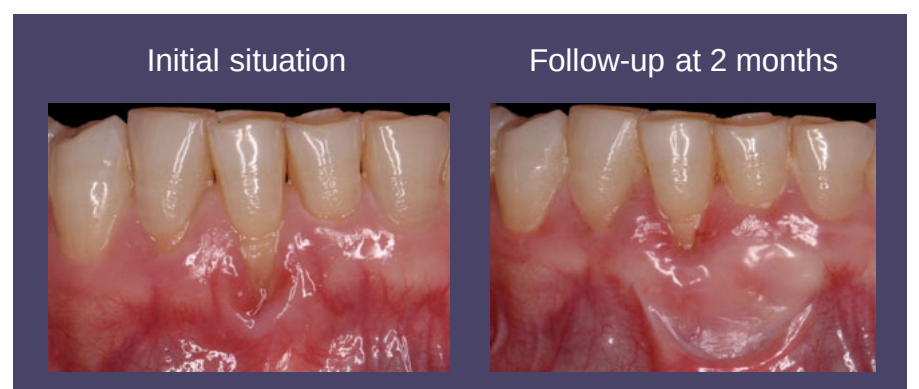
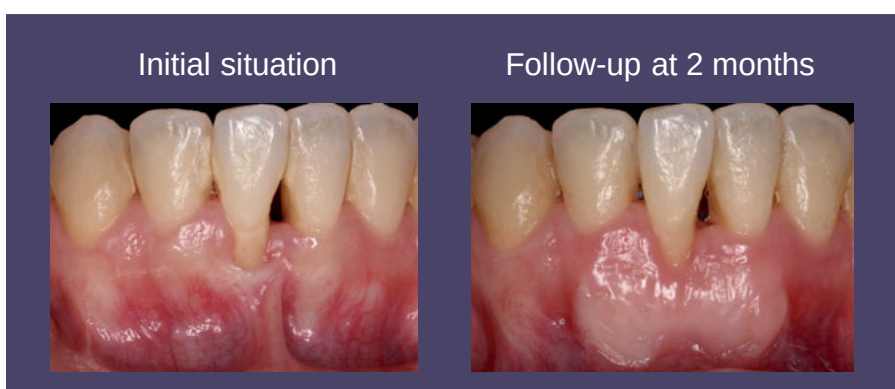
In both cases, the proposed and performed treatment was mucogingival surgery to increase the width of keratinized gingiva, using a free gingival graft (FGG) from the palate.



1 e 2 – Initial situation (frontal and occlusal view); 3 – Incisions; 4 – Split-thickness flap; 5 e 6 – Measurement of the recipient site; 7 – Donor site (palate) before graft removal; 8 – Donor site after graft removal; 9 – Suture of the donor site; 10 e 11 – Measurement of the free gingival graft; 12 – Free gingival graft in the recipient site; 13 e 14 – Graft suture (frontal and occlusal view); 15 – Wound healing at 15 days.



1 – Initial situation (frontal view); 2 – Mechanical debridement of the root surface; 3 – Measurement of gingival recession; 4 – Incisions; 5 – Split-thickness flap; 6 e 7 – Measurement of the recipient site; 8 – Donor site (palate) before graft removal; 9 – Graft removal from the donor site; 10 – Suture of the donor site; 11 e 12 – Measurement of the free gingival graft; 13 – Free gingival graft in the recipient site; 14 – Graft suture (frontal view); 15 – Wound healing at 12 days.



## Discussion

The role played by keratinized gingiva (KG) in the maintenance of periodontal health is controversial. Some authors argue for a need of a minimum width of 2 mm of KG<sup>2</sup>, while others suggest that there may be periodontal health in areas where there is a narrow band of KG or even when it is absent, provided there is an adequate bacterial plaque control<sup>3,4,5</sup>. However, when there is difficulty in maintaining good levels of oral hygiene, as in the presented cases, it should be considered the possibility of increasing the width of KG, in order to avoid the progression of inflammation and the consequent continuous loss of periodontal attachment.

Thus, the augmentation of KG is indicated in the following situations: locations with width less than 2 mm of KG, with an inadequate bacterial plaque control and/or infra-gingival restorations<sup>6,7</sup>; for stabilization of a progressive gingival recession<sup>6,7</sup> and elimination of the frenum with high insertions<sup>6,7</sup>; when there is need to increase the vestibular depth<sup>6,7,8</sup>, increase the soft tissue thickness prior to buccal orthodontic movement and when there are prominent roots and/or bone dehiscences<sup>6,7,9</sup>.

The literature is consensual in demonstrating FGG as the gold standard when it is intended to increase KG<sup>6</sup>, nevertheless other types of autogenous grafts<sup>6</sup> (connective tissue graft with or without epithelial band), as well as substitute materials<sup>7</sup> may be used.

## Conclusions

Regarding the presented cases, the realization of FGG allowed to increase the width of KG and, consequently to improve the periodontal health, creating conditions for its long term maintenance. Thus, it is possible to conclude that, in both cases, the treatment fulfilled the proposed goals: the improvement of the condition and resistance of soft tissues, allowing an effective plaque control by the patients.

## References

- Miller (1985) A classification of marginal tissue recession. *Int J Periodontics Restorative Dent*; 5: 8-13.
- Lang & Loe (1972) The relationship between the width of keratinized gingiva and gingival health. *J Periodontol*; 43: 623-627.
- Miyasato et al. (1977) Gingival condition in areas of minimal and appreciable width of keratinized gingiva. *J Clin Periodontol*; 4: 200-209.
- Hangorsky & Bissada (1980) Clinical assessment of free gingival graft effectiveness on the maintenance of periodontal health. *J Periodontol*; 51: 274-278.
- Dorfman et al. (1982) Longitudinal evaluation of free autogenous gingival grafts. A 4-year report. *J Periodontol*; 53: 349-352.
- Deeb & Deeb (2015) Soft tissue grafting around teeth and implants. *Oral Maxillofac Surg Clin North Am*; 27: 425-448.
- Bertl et al. (2017) Soft tissue substitutes in non-root coverage procedures: a systematic review and meta-analysis. *Clin Oral Investig*; 21: 505-518.
- Scheyer et al. (2015) Periodontal soft tissue non-root coverage procedures: a consensus report from the AAP Regeneration Workshop. *J Periodontol*; 86(2 Suppl): S73-S76.
- Kim & Neiva (2015) Periodontal soft tissue non-root coverage procedures: a systematic review from the AAP Regeneration Workshop. *J Periodontol*; 86(2 Suppl): S56-S72.