



# SINUS LIFT BY CRESTAL APPROACH USING OSSEODENSIFICATION: A CASE REPORT

**PURPOSE:** To allow the placement of an implant on a site with reduced bone height, through a minimally invasive technique of sinus lift by crestal approach.

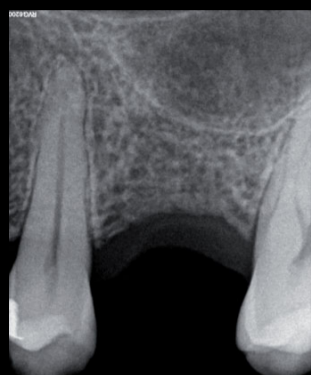

Fig.1

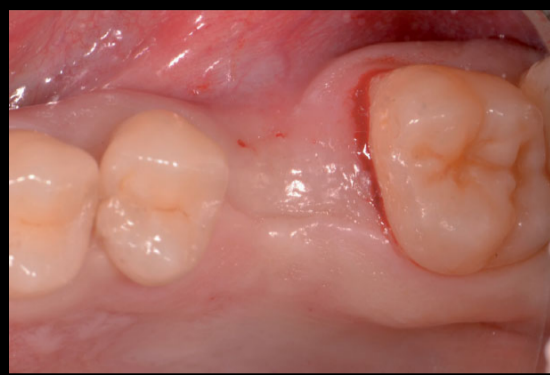

Fig.2

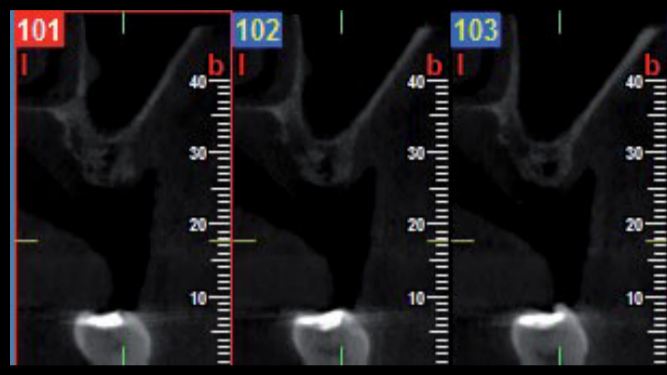


Fig.3

**CASE DESCRIPTION:** A 45-year-old male patient went to our clinic to replace his missing upper left first molar with an implant (Fig. 2). The CBCT indicated a residual bone height of 5-6 mm up to the maxillary sinus (Fig. 3). The treatment plan consisted in sinus lift by crestal approach with osseodensification - a recent technique<sup>1,2</sup> that advocates the use of specific drills in counterclockwise direction which promotes bone expansion and condensation (Fig. 4). Bone graft material (NovaBone<sup>®</sup>) was densified into the sinus with the burs at low-speed (150 rpm) counterclockwise without irrigation (Figs. 5 and 6). After sinus elevation, a platform-switched implant (IDCam 4,2mm x 12mm, IDI<sup>®</sup>) with a morse taper connection was placed.

After 4 months, second stage surgery and final impression were made and a screw retained metal-ceramic crown was fabricated.

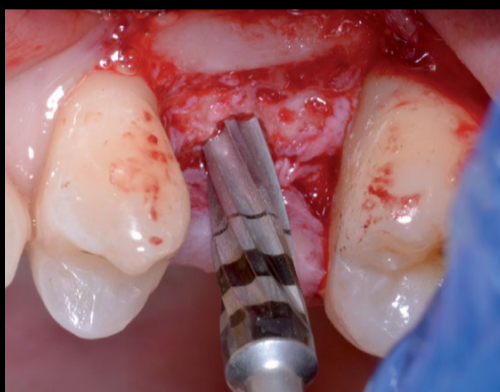


Fig.4

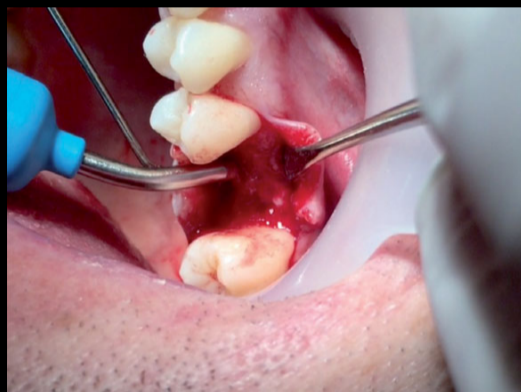


Fig.5

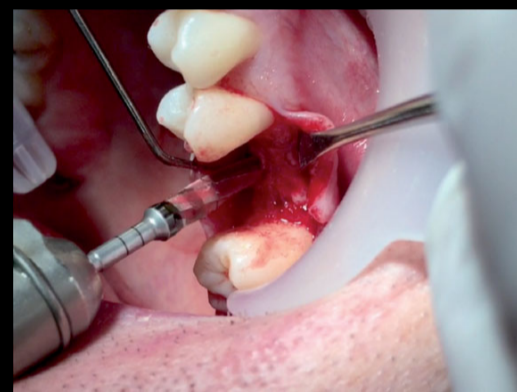


Fig.6

**RESULTS:** The immediate post-operative CBCT showed a successful three-dimensionally regenerative procedure with adequate containment of the graft material and apparent integrity of the Schneiderian membrane (Fig.8). One year after the procedure, it is possible to verify the stability of the case, both clinically and radiographically (Fig. 11 and 12).

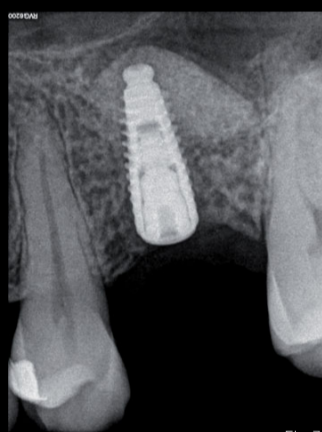


Fig.7

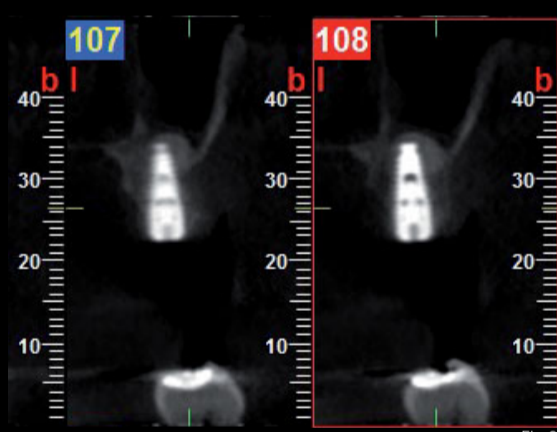


Fig.8

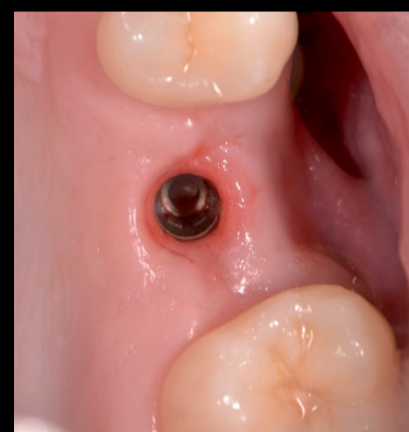


Fig.9

**DISCUSSION:** The concept of osseodensification has changed the paradigm of implant site preparation and it can be applied for maxillary sinus lift by crestal approach in a simple, safe and predictable way with reduced morbidity.

**CONCLUSIONS:** The described procedure was successful, returning aesthetic and masticatory function to the patient.

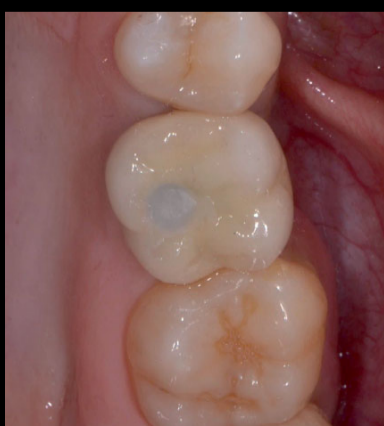

Fig.10

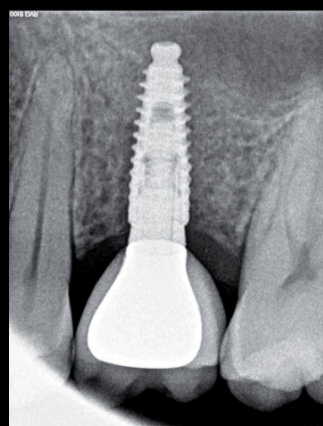


Fig.11

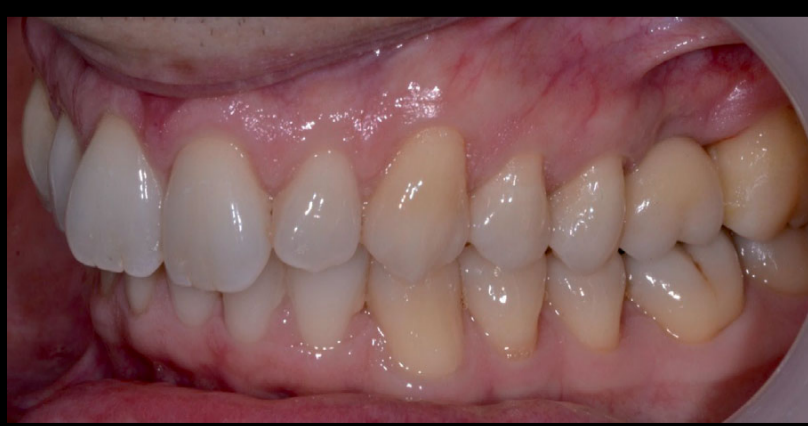

Fig.12

## REFERENCES:

- Huwais S, Meyer EG. A Novel Osseous Densification Approach in Implant Osteotomy Preparation to Increase Biomechanical Primary Stability, Bone Mineral Density, and Bone-to-Implant Contact. *Int J Oral Maxillofac Implants.* 2017 Jan/Feb;32(1):27-36. doi: 10.11607/jomi.4817. Epub 2016 Oct 14.
- Lahens B, et al. Biomechanical and histologic basis of osseodensification drilling for endosteal implant placement in low density bone. An experimental study in sheep. *J Mech Behav Biomed Mater.* 2016 Oct;63:56-65. doi: 10.1016/j.jmbm.2016.06.007. Epub 2016 Jun 10.