

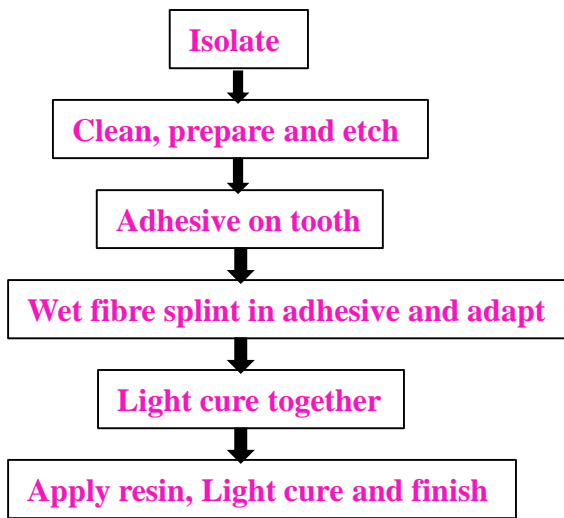
PRAGMATIC WAY TO A PLEASANT SMILE: NATURAL TOOTH PONTIC

Grover .S, Dudy .R, Tewari.S,

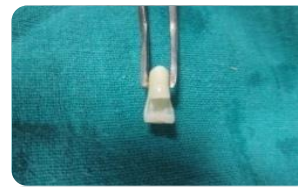INTRODUCTION: Natural tooth pontic is a natural tooth crown used to replace a missing anterior tooth. It is indicated in case of periodontally involved tooth with sound structure that warrants extraction, and is without heavy centric or functional occlusion. No laboratory work is required. It produces immediate results with excellent esthetics, but its limitation is that it is a temporary restoration.

OBJECTIVES: To describe a simple, economical and fast method to replace a single tooth with best esthetics achievable.


MATERIAL AND METHOD: If the tooth is intact, it is easier to use that tooth as a Natural Tooth Pontic and bond it to the adjacent teeth using an indirectly fabricated composite resin framework reinforced with polyethylene fibre. This is a case series of 3 patients where replacement of missing anterior tooth is performed using a fiber composite resin with natural tooth crown as a pontic . Procedure employed is as follows: After 1 week of atraumatic extraction of the involved tooth, the extracted tooth is prepared. The resin fibre (ribbon) is cut according to the template and then the prepared pontic is splinted with adjacent teeth by ribbon.



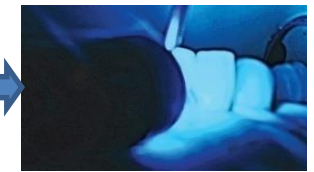
Procedure



Prepared tooth

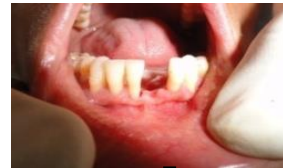

Template preparation using foil and premeasured ribbon fiber

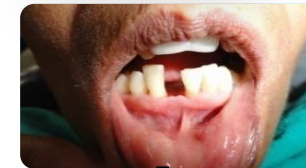

Splinting the prepared pontic with adjacent teeth

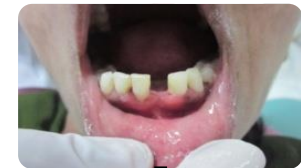Pre-operative



CASE 1

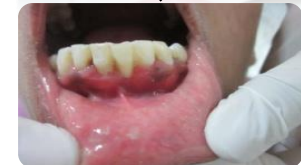
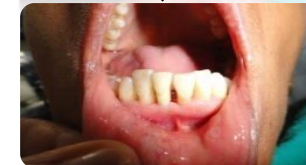
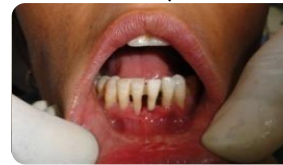CASE 2



CASE 3

Post-operative



RESULTS: 6 months follow up of all cases revealed good results in terms of esthetics, stability and phonetics.

DISCUSSION AND CONCLUSIONS: Appropriate patient selection, their motivation levels, plaque control and precision during placement should be kept in mind to achieve the desired objective. Natural tooth pontic can be placed as an interim restoration until an extraction site heals which later can be replaced by a conventional bridge or an implant.

BIBLIOGRAPHY :

1. Quirynen M, Mongardini C et al. A long term evaluation of composite bonded natural/resin teeth as replacement of lower incisors with terminal periodontitis. J Periodontol 1999;70:205-12.
2. Belli sema, ozer fuzon. A simple method for single anterior tooth replacement. J Adhesive Dent 2000; 2:67-70.